

Aerosolized Prostacyclin and Iloprost in Severe Pulmonary Hypertension

Horst Olschewski, MD; Dieter Walrmath, MD;
Ralph Schermuly, PhD; H. Ardeshir Ghofrani, MD;
Friedrich Grimminger, MD, PhD; and
Werner Seeger, MD

Objective: To compare the effects of aerosolization of prostacyclin and its stable analog iloprost with those of nasal oxygen, inhaled nitric oxide, and intravenous prostacyclin on hemodynamics and gas exchange in patients with severe pulmonary hypertension.

Design: Open uncontrolled trial.

Setting: Justus-Liebig-University, Giessen, Germany.

Patients: 4 patients with primary pulmonary hypertension and 2 patients with severe pulmonary hypertension associated with calcinosis, the Raynaud phenomenon, esophageal dysfunction, sclerodactyly, and telangiectasia (the CREST syndrome). All were classified as New York Heart Association class III or class IV.

Intervention: Short-term applications of O₂, inhaled nitric oxide, intravenous prostacyclin, aerosolized prostacyclin, and aerosolized iloprost during repeated catheter investigation of the right side of the heart within a 1-month period. One patient had long-term therapy with inhaled iloprost.

Results: Aerosolized prostacyclin decreased pulmonary artery pressure in 6 patients from (mean \pm SE) 62.3 \pm 4.1

mm Hg to 50.8 \pm 5.5 mm Hg and reduced pulmonary vascular resistance from 1721 \pm 253 dyne/s \cdot cm⁻⁵ to 1019 \pm 203 dyne/s \cdot cm⁻⁵, and it increased cardiac output from 2.75 \pm 0.21 L/min to 4.11 \pm 0.54 L/min, mixed venous oxygen saturation from 51.1% \pm 3.4% to 66.3% \pm 4.1%, and arterial oxygen saturation from 90.6% \pm 2.7% to 93.8% \pm 2.3% (P < 0.05 for all changes). Mean systemic arterial pressure was only slightly affected. The responses lasted for 10 to 30 minutes after inhalation was terminated. Aerosolized iloprost had an identical efficacy profile but was associated with a longer duration of the pulmonary vasodilatory effect (60 min to 120 min). In comparison, intravenous prostacyclin reduced pulmonary vascular resistance with corresponding efficacy but produced a more pronounced decline in systemic artery pressure and no clinically significant decrease in pulmonary artery pressure. Nitric oxide and O₂ were less potent pulmonary vasodilators in these patients. In one patient, 1 year of therapy with aerosolized iloprost (100 μ g/d in six aerosol doses) resulted in sustained efficacy of the inhaled vasodilator regimen and clinical improvement.

Conclusion: Aerosolization of prostacyclin or its stable analog iloprost causes selective pulmonary vasodilatation, increases cardiac output, and improves venous and arterial oxygenation in patients with severe pulmonary hypertension. Thus, it may offer a new strategy for treatment of this disease.

Ann Intern Med. 1996;124:820-824.

Primary pulmonary hypertension is a progressive fatal disease of unknown cause, and patients with this condition have a median life expectancy of less than 3 years after diagnosis (1). Death is most closely associated with an increase in pulmonary artery pressure and right atrial pressure and a decrease in cardiac output due to failure of the right side of the heart. The responsiveness of pulmonary hypertension to various vasodilator agents led to the speculation that, concomitant with vascular remodeling processes, persistent vasoconstriction is an important feature of the disease. Long-term use of calcium-channel blockers improves the survival rate in approximately 25% of patients; in such patients, the response to these drugs is a substantial decrease in pulmonary artery pressure and pulmonary vascular resistance (2). The main hazards of this therapy are systemic hypotension and worsening of right ventricular function. Intravenous prostacyclin is a potent pulmonary vasodilator in patients with primary pulmonary hypertension, but it requires continuous intravenous access and, like calcium antagonists, lacks selectivity for the lung vasculature (3-6). We recently used aerosol techniques for preferential distribution of prostacyclin to well-ventilated lung areas, thereby achieving selective pulmonary vasodilatation with a concomitant improvement of venti-

From Justus-Liebig-University, Giessen, Germany. For current author addresses, see end of text.

lation-perfusion matching in mechanically ventilated patients with the adult respiratory distress syndrome (7). This approach has also been shown to be effective in hypoxia-induced pulmonary hypertension in dogs (8). We extended this strategy by nebulizing prostacyclin and a stable analog, iloprost, in patients with severe pulmonary hypertension.

Methods

Four patients with primary pulmonary hypertension and two patients with severe pulmonary hypertension associated with calcinosis, the Raynaud phenomenon, esophageal dysfunction, sclerodactyly, and telangiectasia (the CREST syndrome), all of whom were classified as New York Heart Association class III or class IV. Patients gave informed consent to the test trial, which was approved by the institutional ethics committee of Justus-Liebig-University, Giessen, Germany. Two of the patients with primary pulmonary hypertension (patient A, 30 years of age, and patient B, 31 years of age) developed the disease several months after pregnancy. In the other two patients with pulmonary hypertension (patient C, a 37-year-old man, and patient D, a 56-year-old woman), no trigger was identified. The patients with the CREST syndrome (patient E, a 56-year-old woman who had received a diagnosis of the syndrome 2 years earlier, and patient F, a 54-year-old woman who had received this diagnosis 15 years earlier) had no involvement of the inner organs and had never received immunosuppressive therapy other than low-dose corticosteroids. Pulmonary embolism was excluded by pulmonary angiograms and ventilation and perfusion lung scans in each patient. Chest radiography and high-resolution computed tomography showed no lung fibrosis, and pulmonary function testing showed no evidence of obstructive or restrictive lung disease. Only one patient (patient B) responded to calcium antagonists according to the criteria given by Rich and colleagues (2). Long-term therapy included anticoagulation and diuretics (in all patients) and low-dose steroids (in patients E and F).

A fiberoptic thermodilution pulmonary artery catheter was used to measure central venous pressure, pulmonary artery pressure, pulmonary artery wedge pressure, cardiac output, and venous oxygen saturation; a femoral artery catheter was used to assess mean arterial pressure and arterial oxygen saturation. In each test trial, the following were administered:

1. Oxygen, 2 to 8 L/min.
2. Inhaled nitric oxide, 10 to 28 parts per million.
3. Intravenous prostacyclin (epoprostenol sodium, Wellcome Research Laboratories, Beckenham, Kent,

United Kingdom), increased in increments of 2.5 ng/kg · min⁻¹ until patients had discomfort (thoracic oppression, heat, or headache) or until mean arterial pressure decreased to less than 70 mm Hg. The highest tolerable dose (5 to 7.5 ng/kg · min⁻¹) was continued for 20 minutes.

4. Aerosolized prostacyclin (25 to 50 µg of glycine buffer per mL), jet-nebulized with room air at a pressure of 153 kPa (fluid flux, 0.15 mL/min; mass median aerodynamic diameter of particles, 2.9 µm; geometric SD, 3.1, ascertained by impactor technique) and delivered to a spacer connected to the afferent limb of a y-valve mouthpiece for 15 minutes (total nebulized dose, 52 to 112 µg).

5. Aerosolized iloprost (Ilomedin, Schering AG, Berlin, Germany) (5 to 10 µg of saline per mL), administered according to prostacyclin (total nebulized dose, 9 to 21 µg).

Patients were tested on a separate day for the presence of calcium antagonists (data not shown). All other measurements were taken before, during, and after application of each test trial challenge. The time between the different maneuvers was sufficient for a new stable baseline period. The number of challenges required 10 hours for one entire trial sequence. These trials were done twice within a 1-month period in all patients, and the data were averaged (except for the data from patient B, who took part in only one test trial). One patient (patient E) subsequently began receiving long-term treatment with aerosolized iloprost (100 µg/d, divided into six aerosol doses), which has now been continued for 1.5 years.

Values before and after challenge in six patients are given for each challenge and are expressed as mean ± SD. We tested these values for significance using the two-tailed Student *t*-test for intrapair differences; these levels of significance are given.

Results

In all six patients, the high pulmonary artery pressure and pulmonary vascular resistance values, the low cardiac output and venous oxygen saturation values, and the increased central venous pressure value indicated advanced disease (Table 1). As we had anticipated, arterial and venous oxygen saturation values increased with oxygen, but hemodynamics improved only moderately. Inhaled nitric oxide substantially decreased pulmonary artery pressure, pulmonary vascular resistance, and central venous pressure and increased cardiac output and venous oxygen saturation. Inhalation only moderately decreased systemic vascular resistance. After cessation of nitric oxide therapy, values returned to baseline within 2 to 5 minutes. Intravenous prostacyclin

Table 1. Hemodynamics and Gas Exchange in Response to Acute Exposure to Vasoactive Agents*

Variable	Before O ₂	During O ₂	Before NO	During NO	Before Intra-venous PG	During Intra-venous PG	Before Aero-solized PG	During Aero-solized PG
Pulmonary artery pressure, mm Hg	58.2 ± 2.6	55.2 ± 2.4	60.4 ± 3.1	54.2 ± 4.3†	62.7 ± 4.5	59.8 ± 5.6	62.3 ± 4.1	50.8 ± 5.5‡
Cardiac output, L/min	2.76 ± 0.20	2.78 ± 0.12	2.80 ± 0.17	3.48 ± 0.21†	2.94 ± 0.24	4.52 ± 0.42‡	2.75 ± 0.21	4.11 ± 0.54‡
Pulmonary vascular resistance, dynes · cm ⁻⁵	1537 ± 173	1465 ± 138	1578 ± 146	1141 ± 141‡	1551 ± 186	1000 ± 158‡	1721 ± 253	1019 ± 203‡
Central venous pressure, mm Hg	13.3 ± 1.2	13.7 ± 1.1	13.7 ± 0.9	10.2 ± 0.8‡	13.8 ± 1.7	12.9 ± 1.5	13.6 ± 1.6	10.2 ± 1.6†
Mean artery pressure, mm Hg	96 ± 4	97 ± 5	97 ± 5	97 ± 5	100 ± 6	87 ± 6‡	96 ± 6	90 ± 6
Systemic vascular resistance, dynes · cm ⁻⁵	2459 ± 191	2496 ± 183	2413 ± 160	2064 ± 178†	2453 ± 206	1398 ± 169‡	2400 ± 173	1680 ± 229‡
Heart rate, beats/min	91.0 ± 3.4	87.9 ± 3.1	96.4 ± 3.2	93.7 ± 3.2	101.8 ± 4.2	106.5 ± 5.0‡	102.1 ± 4.2	99.1 ± 4.8
Arterial oxygen saturation, %	90.4 ± 1.9	97.6 ± 1.0‡	89.4 ± 2.9	90.0 ± 3.1	89.0 ± 3.3	88.8 ± 3.4	90.6 ± 2.7	93.8 ± 2.3†
Venous oxygen saturation, %	57.7 ± 2.6	65.1 ± 1.9‡	57.0 ± 3.8	62.7 ± 5.0†	53.4 ± 4.5	66.7 ± 5.2‡	51.1 ± 3.4	66.3 ± 4.1‡

* O₂ = nasal oxygen, 2 to 8 L/min; NO = inhaled nitric oxide, 10 to 28 parts per million; PG = prostacyclin. Values are presented as mean ± SE for six patients. The intravenous prostacyclin dose was 5 to 7.5 ng/kg · min⁻¹; the aerosolized prostacyclin dose was 52 to 112 µg.

† *P* < 0.05 for comparisons between values before and after drug therapy.

‡ *P* < 0.01 for comparisons between values before and after drug therapy.

substantially decreased pulmonary vascular resistance and increased cardiac output in all patients, resulting in a modest decline of pulmonary artery pressure but a substantial decrease in systemic arterial pressure and an increase in heart rate due to peripheral vasodilatation. Aerosolized prostacyclin achieved the same reduction in pulmonary vascular resistance with a smaller increase in cardiac output but a significant decline in pulmonary artery pressure. Moreover, arterial oxygen saturation values were increased with aerosolized prostacyclin but remained unchanged, on average, after intravenous prostanoid application. In all patients, the stable prostacyclin analog iloprost caused nearly identical changes in hemodynamics and gas exchange (example given in Figure 1, further data not shown). The effects of iloprost, however, lasted longer: After termination of aerosolization, prostacyclin-induced changes returned to baseline within 10 to 30 minutes and iloprost-induced changes, within 60 to 120 minutes.

Because response to inhaled prostanoids was favorable, we initiated regular long-term therapy with aerosolized iloprost in one patient (patient E; see Figure 1). Daily inhalation of the prostanoid was well tolerated, and sustained responsiveness of the pulmonary vasculature was seen over a 1-year period. This patient's New York Heart Association class improved from IV to III, and her CREST-related skin lesions healed.

Discussion

Prostacyclin is one of the most potent pulmonary vasodilatory agents available for clinical purposes. Moreover, in severe pulmonary hypertension, local deficiencies of prostacyclin may play a role in the genesis and progression of vascular remodeling (4). Accordingly, long-term therapy with high doses of

prostacyclin resulted in increased life expectancy and exercise tolerance (6). We describe a technique of intra-alveolar deposition of prostacyclin in patients with severe pulmonary hypertension. The acute effects on pulmonary vascular resistance seen with this technique corresponded to those of intravenous prostacyclin, but selectivity for the pulmonary circulation was achieved, as indicated by a substantial decrease of pulmonary artery pressure and a smaller effect on systemic arterial pressure. Moreover, preferential distribution of the aerosolized vasodilator to the best-ventilated lung areas, which improved ventilation-perfusion matching, was suggested by an increase in arterial oxygen saturation. This effect was even superior to that of inhaled nitric oxide, which has previously been shown to cause selective pulmonary vasodilatation in patients with severe pulmonary hypertension (9, 10). We found that the nitric oxide-evoked decrease in pulmonary vascular resistance was less than that seen in response to inhaled or intravenous prostacyclin in all patients.

Iloprost showed an identical efficacy profile but a longer duration of pulmonary vasodilatation in comparison with prostacyclin. It was well tolerated in the patient who received long-term therapy with daily inhalations of this drug, and sustained responsiveness of the pulmonary vasculature was seen. Interestingly, the beneficial effects were achieved by a total aerosolized iloprost quantity of 100 µg/d, which corresponds to a dosage of only approximately 1.1 ng/kg · min⁻¹. This is remarkable because the aerosol fraction being deposited in the alveolar spaces is commonly estimated to range from less than 10% to 15%. In addition, contrasting with the current experience with continuous prostacyclin infusion (6), we noted no need to increase the dosage. Our study is limited in that only a small number of patients were investigated, and long-term application was only used in one patient. Moreover, the

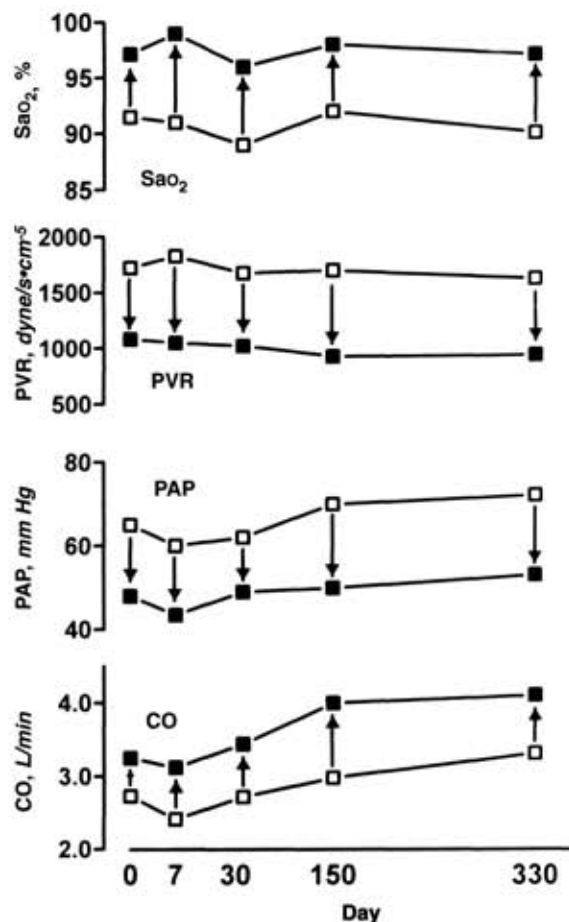
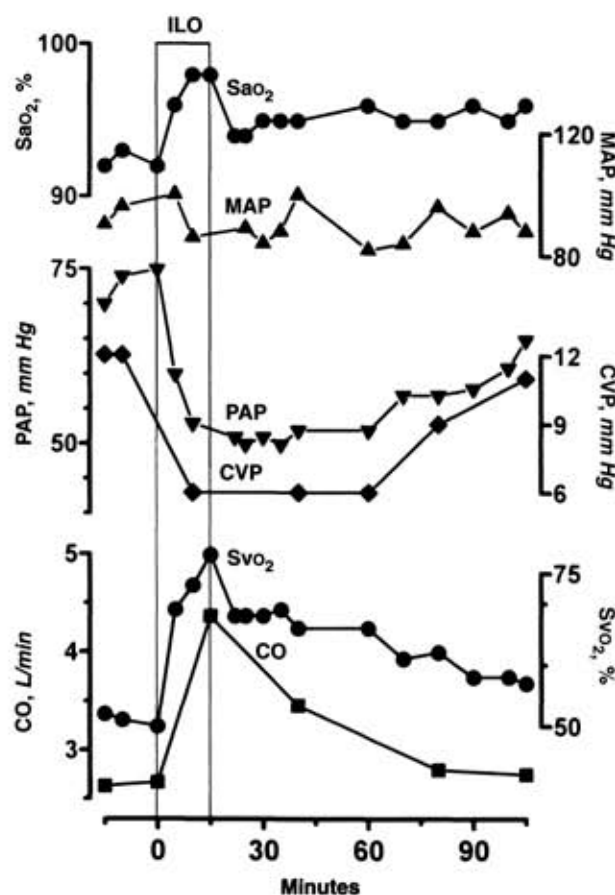


Figure 1. Short- and long-term effects of iloprost inhalation in one patient. **Left.** Example of the hemodynamic and gas exchange response to one 15-minute iloprost inhalation (white bar, ILO) in patient E, who received long-term treatment with inhalations of 100 µg of iloprost daily. During inhalation, cardiac output (CO) and venous oxygen saturation (Svo₂) increased sharply. Simultaneously, mean pulmonary artery pressure (PAP) and central venous pressure (CVP) decreased. Note the almost constant mean arterial pressure (MAP) and increasing arterial oxygen saturation (Sao₂) in response to inhalation. **Right.** Time course of hemodynamics and arterial oxygen saturation in response to long-term iloprost aerosolization, 100 µg/d in six aerosol doses, in patient E. Baseline values (open squares, assessed in the morning before daily inhalation) of Sao₂, pulmonary vascular resistance (PVR), PAP, and CO, and those values obtained immediately after aerosolization of the first 17 µg of the daily iloprost dose are shown. Note that the acute responses to inhalation (arrows) did not decrease during long-term therapy.

short duration of pulmonary vasodilatation even in response to the stable prostacyclin analog requires frequent dosage of the aerosolized drug. The long-term effects of repetitive alveolar prostacyclin deposition in addition to pulmonary vascular changes need to be carefully addressed in further studies.

In conclusion, aerosolization of prostacyclin and its stable analog iloprost, substances with well-known pharmacologic profiles, caused marked pulmonary vasodilatation in patients with severe pulmonary hypertension. Inhalation appeared to be reliable and safe. In contrast to continuous infusion of these prostanoids, which is cumbersome and prone to hazards caused by intravenous line complications, selectivity for the pulmonary circulation was achieved concomitantly with an improvement of arterial oxygenation. This strategy may thus be suitable for bridging to lung or heart-lung transplantation. Moreover, considering that local deficiencies of prostacyclin may play a role in the genesis of severe pulmonary hypertension, high doses of lo-

cally deposited prostanoids might favorably affect vascular remodeling processes in addition to having immediate vasodilatory efficacy.

Acknowledgments: The authors thank Dr. R.H. Bödeker, Institute of Medical Statistics, for statistical discussion and Dr. R. Snipes, Institute of Anatomy, Justus-Liebig-University, Giessen, Germany, for linguistic revision of the manuscript.

Requests for Reprints: Werner Seeger, MD, Department of Medicine, Justus-Liebig-University, Klinikstrasse 36, D-35392 Giessen, Germany.

Current Author Addresses: Drs. Olschewski, Walrath, Schermuly, Ghofrani, Grimminger, and Seeger: Department of Medicine, Justus-Liebig-University, Klinikstrasse 36, D-35392 Giessen, Germany.

References

1. D'Alonzo GE, Barst RJ, Ayres SM, Bergofsky E, Brundage BH, Detre KM, et al. Survival in patients with primary pulmonary hypertension. Results from a national prospective registry. *Ann Intern Med.* 1991;115:343-9.

2. Rich S, Kaufmann E, Levy PS. The effect of high doses of calcium-channel blockers on survival in primary pulmonary hypertension. *N Engl J Med*. 1992; 327:76-81.
3. Higenbottam T, Wheeldon D, Wells F, Wallwork J. Long-term treatment of primary pulmonary hypertension with continuous intravenous epoprostenol (prostacyclin). *Lancet*. 1984;1:1046-7.
4. Higenbottam T. The place of prostacyclin in the clinical management of primary pulmonary hypertension. *Am Rev Respir Dis*. 1987;136:782-5.
5. Rubin LJ, Mendoza J, Hood M, McGoon M, Barst R, Williams WB, et al. Treatment of primary pulmonary hypertension with continuous intravenous prostacyclin (epoprostenol). Results of a randomized trial. *Ann Intern Med*. 1990;112:485-91.
6. Barst RJ, Rubin LJ, McGoon MD, Caldwell EJ, Long WA, Levy PS. Survival in primary pulmonary hypertension with long-term continuous intravenous prostacyclin. *Ann Intern Med*. 1994;121:409-15.
7. Walmrath D, Schneider T, Pilch J, Grimminger F, Seeger W. Aerosolised prostacyclin in adult respiratory distress syndrome. *Lancet*. 1993;342:961-2.
8. Welte M, Zwissler B, Habazettl H, Messmer K. PGI₂ aerosol versus nitric oxide for selective pulmonary vasodilation in hypoxic pulmonary vasoconstriction. *Eur Surg Res*. 1993;25:329-40.
9. Pepke-Zaba J, Higenbottam TW, Dinh-Xuan AT, Stone D, Wallwork J. Inhaled nitric oxide as a cause of selective pulmonary vasodilatation in pulmonary hypertension. *Lancet*. 1991;338:1173-4.
10. Zapol WM, Rimar S, Gillis N, Marletta M, Bosken CH. Nitric oxide and the lung. *Am J Respir Crit Care Med*. 1994;149:1375-80.

© 1996 American College of Physicians

In my mechanical way I read all I could find about the affliction, and each word more brought its own gloom. Emphysema, it emerged, could become a torture of the body beyond even my mother's suffering or the holocaust of cancer itself. . . . Somehow through all the null medical words—*generalized overdistension, difficulty of exhalation, excess mucus*—I came to picture the disaster happening in my father's lungs as a pattern like the splotched burning of a sagebrush fire. Perhaps it was the years of blue haze drifting up from his cigarettes that made me think of smolder and flamelick. For whatever reason, the image came to me of the black turf that such a fire spreads in its steady searing fan across the land, and the thought too that there would be no grass-bright greening in this fire's wake as time passed. Only char and more char.

Ivan Doig
This House of Sky: Landscape of a Western Mind

Submitted by:
 Erik R. Swendon, MD
 Department of Veterans Affairs Medical Center
 Seattle, WA 98108

Submissions from readers are welcomed. If the quotation is published, the sender's name will be acknowledged. Please include a complete citation, as done for any reference.—*The Editor*